



Successful endoscopic management of a large esophageal defect due to Boerhaave syndrome with endoscopic vacuum therapy using vacuum sponge and vacuum stent

Lisanne M. D. Pattynama, MD,^{1,2} Wietse J. Eshuis, MD, PhD,² Mattheus C. B. Wielenga, MD, PhD,³ Roos E. Pouw, MD, PhD³

INTRODUCTION

Endoscopic vacuum therapy (EVT) is an efficient new treatment option for the management of upper GI transmural defects.¹⁻⁴ Using an endoscopically placed sponge, we applied negative pressure, resulting in drainage of exudate, stimulation of perfusion, and secondary wound healing.⁵ In our center, EVT in the upper GI tract has become standard treatment for esophageal leaks since 2018, using the EsoSponge (B. Braun, Melsungen, Germany).

Recently, the VACStent (MICRO-TECH Europe GmbH, Düsseldorf, Germany) was introduced, which consists of a covered stent surrounded by a sponge (Fig. 1). The VACStent combines sealing of the defect with the benefits of negative pressure therapy, which also keeps the VACStent in place and the lumen open. The VACStent seems to be a promising, safe, and feasible treatment option.⁶

CASE

A 63-year-old man was admitted with acute chest pain after vomiting. A CT scan showed a defect of 4 cm in length in the distal esophagus, with a cavity extending proximally into the mediastinum. In close consultation with the surgical department, it was decided to perform an endoscopy, and a large contaminated cavity was seen (Fig. 2). After cleaning the cavity, a multidisciplinary decision was made to place an EsoSponge intraluminally to cover the defect, since placing an EsoSponge into the cavity was unsuccessful

Abbreviation: EVT, endoscopic vacuum therapy.

Copyright © 2023 American Society for Gastrointestinal Endoscopy. Published by Elsevier Inc. This is an open access article under the CC BY license (<http://creativecommons.org/licenses/by/4.0/>).

2468-4481

<https://doi.org/10.1016/j.vgie.2022.12.001>

Department of Gastroenterology and Hepatology, Amsterdam UMC, Location University of Amsterdam, Amsterdam, The Netherlands (1), Department of Surgery, Amsterdam UMC, Location University of Amsterdam, Amsterdam, The Netherlands (2), Department of Gastroenterology and Hepatology, Amsterdam UMC, Location Vrije Universiteit, Amsterdam, The Netherlands (3).

because of the sharp angle upward. A feeding tube was placed alongside the EsoSponge for enteral feeding.

During EVT, a negative pressure of 75 to 125 mm Hg was applied, and the EsoSponge was exchanged every 3 to 7 days. After initial clinical improvement, little healing tendency of the defect was observed with endoscopy and CT imaging, and the decrease of infectious parameters was stagnant. Therefore, after 37 days of EVT, it was decided to perform surgical decortication and placement of a muscle flap into the cavity (Fig. 3).

Subsequently, intraluminal EVT with EsoSponge was continued to optimize granulation of the defect. However, after 23 days, infectious parameters increased and a CT scan showed expansion of the paraesophageal collection. Furthermore, endoscopic improvement was stagnant. Therefore, it was decided to place a VACStent.

PROCEDURE AND TREATMENT COURSE

The procedure was performed with the patient under deep propofol sedation using a diagnostic endoscope (GIF-EZ1500; Olympus, Tokyo, Japan). First, the EsoSponge was removed, revealing the remaining defect with air bubbles at the proximal site (Fig. 4).

Second, a stiff 0.035-inch guidewire (600375-5 Classic; MICRO-TECH Europe GmbH) was placed into the duodenum. The VACStent was advanced over the guidewire. After reintroduction of the endoscope, the VACStent was positioned over the defect under endoscopic visualization, and the VACStent was deployed (Figs. 5 and 6; Video 1, available online at www.giejournal.org). Subsequently, the suction catheter was guided through the nose and connected to a vacuum pump (ActiV.A.C.; 3M Health Care, St. Paul, Minn, USA). Lastly, 125 mm Hg negative pressure was applied and decreased to 75 mm Hg negative pressure the next day.

From the second day after VACStent placement, oral intake was extended to a soft diet without problems. After 7 days, the VACStent was removed using a tapered hood distal attachment cap (DH-28GR Hood; FUJIFILM Corporation, Tokyo, Japan) to carefully separate the stent from the mucosa (Fig. 7). Subsequently, the stent was removed with a grasping forceps.




Figure 1. VACStent with fully covered nitinol stent (length 72 mm, diameter 30-14-30 mm), polyurethane sponge (length 50 mm), and blue suction catheter. Image courtesy of Esophageal Research Team AUMC.

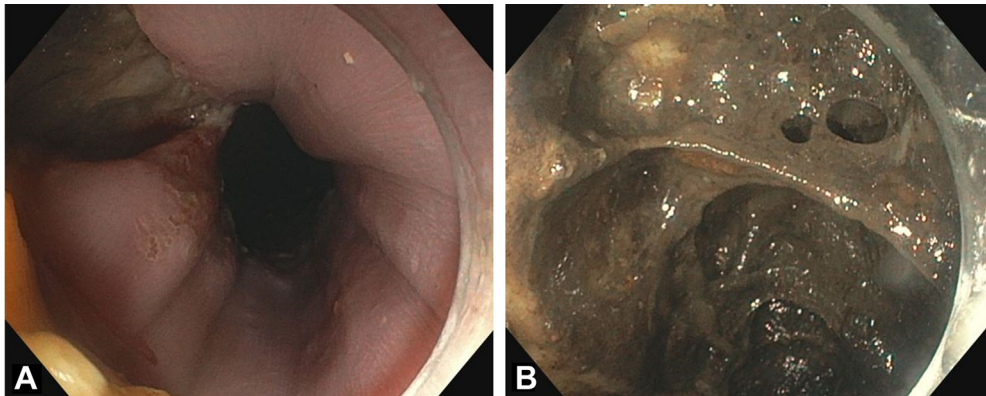


Figure 2. Esophageal perforation (A) and adjacent cavity (B) during first endoscopy.

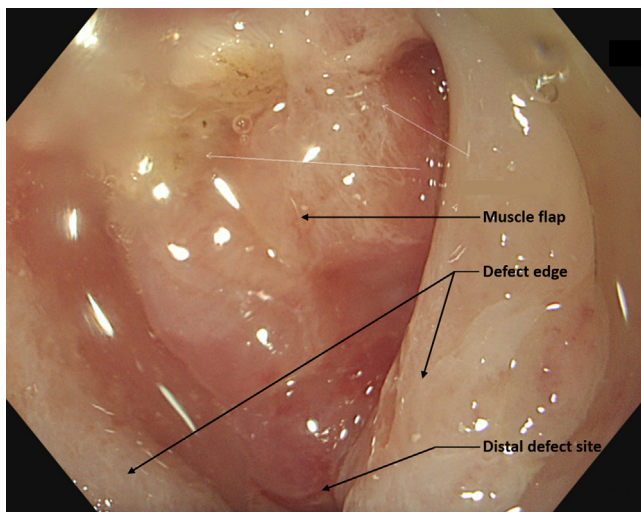


Figure 3. Defect after surgical placement of muscle flap into the cavity.

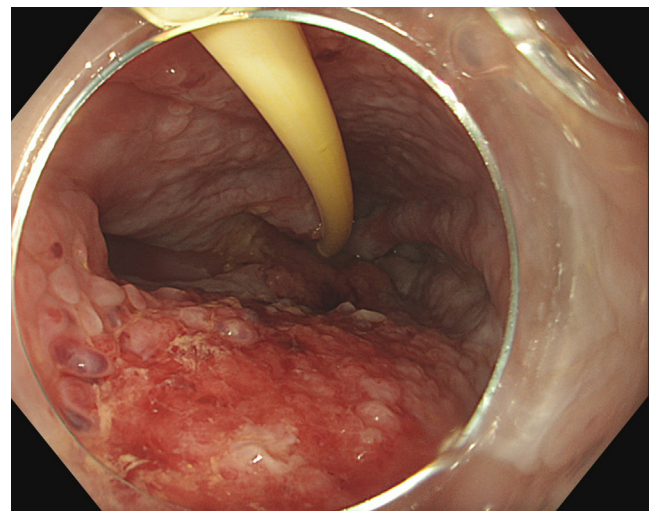


Figure 4. Remaining defect after endoscopic vacuum therapy with 7 sponge exchanges; feeding tube is still in situ.

The defect had become smaller, infectious parameters had decreased, and the patient was clinically stable. However, the suspicion of a persisting defect remained because of some air bubbles, and another VACStent was placed. Upon removal after 1 week, the defect appeared to be

closed (Fig. 8), which was confirmed by a CT scan with oral contrast. Three days after VACStent removal and after 2.5 months of hospitalization, the patient was discharged. At 3 months' follow-up, the patient was doing well and had a normal oral intake.

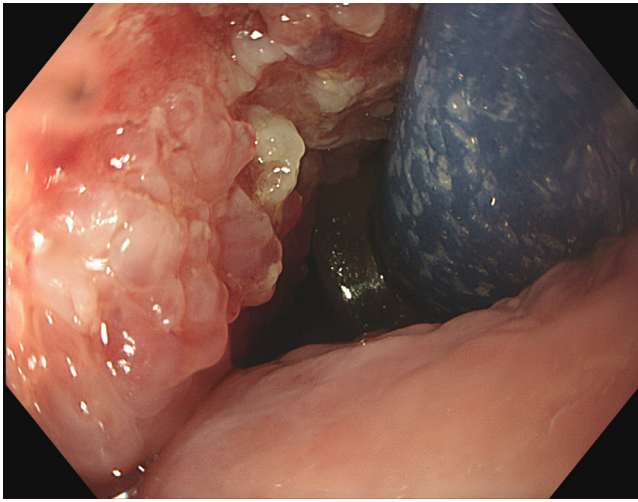


Figure 5. Positioning of VACStent over defect.

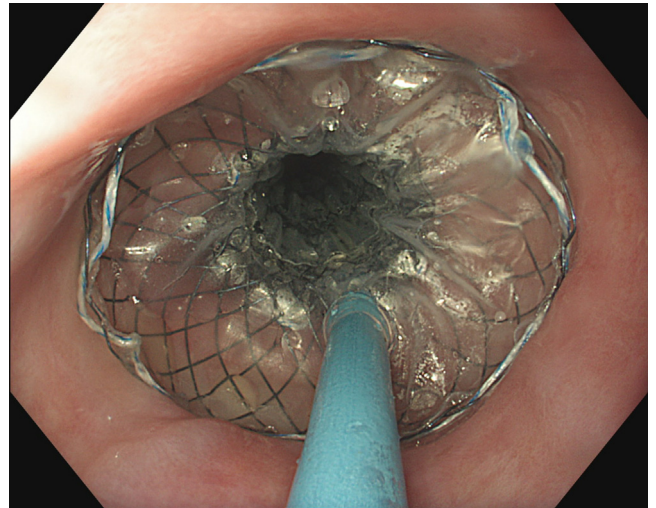


Figure 6. VACStent after intraluminal deployment.

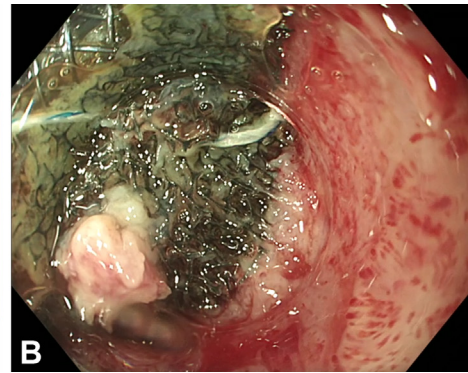
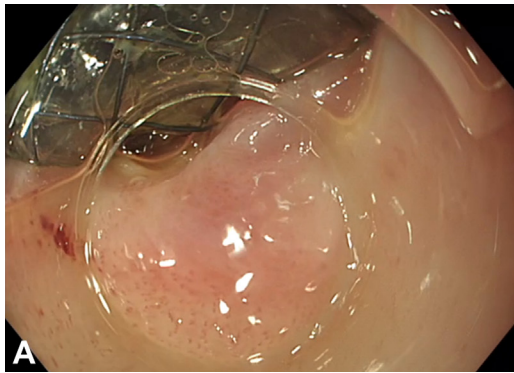


Figure 7. Separation of uncovered part of stent (A) and sponge (B) of the VACStent from the mucosa with a tapered hood distal attachment cap.

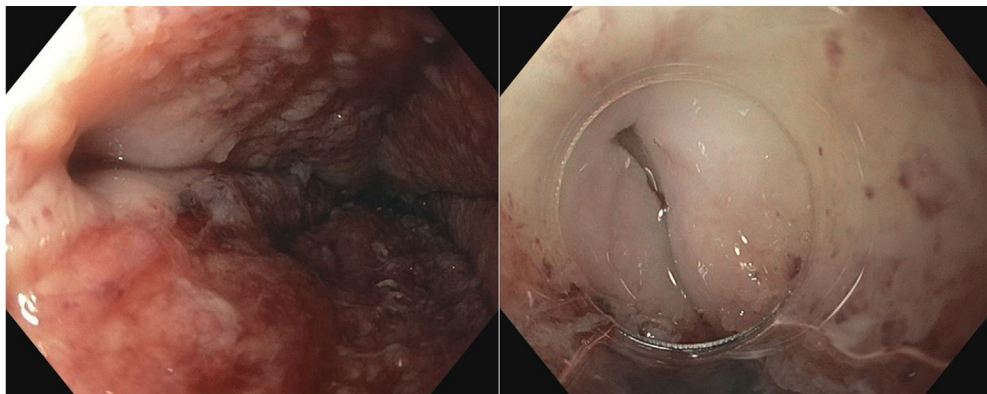


Figure 8. Closed defect after VACStent.

DISCLOSURES

Dr Pouw is a consultant for MicroTech Endoscopy and Medtronic, is a paid speaker for Pentax Medical, and is on an advisory board for EsoCap. All other authors disclosed no financial relationships.

REFERENCES

1. Tavares G, Tustumi F, Tristao LS, et al. Endoscopic vacuum therapy for anastomotic leak in esophagectomy and total gastrectomy: a systematic review and meta-analysis. *Dis Esophagus* 2021;34:doaa132.
2. Scognamiglio P, Reeh M, Karstens K, et al. Endoscopic vacuum therapy versus stenting for postoperative esophago-enteric anastomotic leakage: systematic review and meta-analysis. *Endoscopy* 2020;52:632-42.
3. do Monte Junior ES, de Moura DTH, Ribeiro IB, et al. Endoscopic vacuum therapy versus endoscopic stenting for upper gastrointestinal transmural defects: Systematic review and meta-analysis. *Dig Endosc* 2021;33:892-902.
4. Schniewind B, Schafmayer C, Voehrs G, et al. Endoscopic endoluminal vacuum therapy is superior to other regimens in managing anastomotic leakage after esophagectomy: a comparative retrospective study. *Surg Endosc* 2013;27:3883-90.
5. de Moura DTH, de Moura B, Manfredi MA, et al. Role of endoscopic vacuum therapy in the management of gastrointestinal transmural defects. *World J Gastrointest Endosc* 2019;11:329-44.
6. Chon SH, Scherdel J, Rieck I, et al. A new hybrid stent using endoscopic vacuum therapy in treating esophageal leaks: a prospective single-center experience of its safety and feasibility with mid-term follow-up. *Dis Esophagus* 2022;35:doab067.

Submit to *VideoGIE*

VideoGIE is now indexed in PubMed Central.

VideoGIE is an Open Access, online-only journal indexed in PubMed Central. Submit video cases of endoscopic procedures used in the study, diagnosis, and treatment of digestive diseases.

VideoGIE publishes the following article types:

- **Case Reports:** Reports of the diagnosis and management of digestive diseases using a single case.
- **Case Series:** Reports of the diagnosis and management of digestive diseases using 3 or more cases.
- **Tools and Techniques:** Educational videos demonstrating the use of a particular endoscopic tool or technique. The goal of this section is to help trainees, endoscopy nurses, and technicians learn how best to use the tools of endoscopy for high-quality care.

All manuscripts must be submitted online at <http://www.editorialmanager.com/vgie>